

**MINISTRY OF HEALTH OF UKRAINE
POLTAVA STATE MEDICAL UNIVERSITY**

Department of general surgery

**METHODICAL INSTRUCTIONS
FOR STUDENT SELF-DIRECTED WORK
WHEN PREPARING FOR AND DURING PRACTICAL CLASS**

Study discipline	General surgery
Module №1	INTRODUCTION TO SURGERY. SURGICAL EMERGENCY CONDITIONS. FUNDAMENTALS OF ANESTHESIOLOGY AND INTENSIVE CARE
Content module 1.	Introductions in surgery. Bandages. Asepsis and antisepsis. Peculiarities of care of surgical patients
Lesson theme №1	Desmurgy. Definition. Overlay rules and types of bandages. Typical bandages on the upper extremities, head, neck, thorax.
Years of study	<i>III</i>
Faculty	International

Poltava

Content module 1.	Introductions in surgery. Bandages. Asepsis and
--------------------------	---

	antiseptics. Peculiarities of care of surgical patients
Lesson theme №1	Desmurgy. Definition. Overlay rules and types of bandages. Typical bandages on the upper extremities, head, neck, thorax.

1. Relevance of the topic:

Desmurgy, as a section of general surgery, studies dressings designed for different purposes, mainly where the dressing is fixed or kept for the required period on a wound or area of damage. A doctor of any profession needs the knowledge of desmurgy to provide first aid to victims.

Definitions, rules for applying bandage dressings. Know the types of bandage dressings. Typical dressings on the upper limb, chest, neck, chest.

2. Learning objectives:

Know:

- types of dressing depending on the purpose;
- functional position of the limb;
- classification of dressings.

Be able to:

- apply different soft dressings;
- apply tires and plaster casts.

3. Basic knowledge, skills needed to study the topic

(interdisciplinary integration)

Disciplines	Know	Know
Previous		
Anatomy	Anatomical structure of the skeleton, muscle tissue, chest organs, stomach	Determine the anatomical placement of bones and joints.
Pharmacology	Anesthetics, antishock agents	The use of a variety of medical anti-shock therapy agents.
Future		
Traumatology and orthopedics	Classification, pathogenesis and clinical signs of fractures and dislocation.	Diagnose fractures and dislocations, provide first aid, determine a treatment plan.
Faculty Hospital Surgery	Clinical signs of various injuries of soft tissues, chest and abdominal cavity.	Diagnose and provide first aid to injured dislocations.
Intrasubject		
Aseptics and antiseptics	Rules of asepsis and antiseptics	Apply an aseptic dressing.
Bleeding	Principles of stopping bleeding	Stop the bleeding

Wounds	The clinical picture and first aid for wounds.	Revision early, provide first aid.
Traumatology and orthopedics	Classification, pathogenesis and clinical signs of fractures and dislocations.	Diagnose fractures and dislocations, provide first aid, determine a treatment plan
Faculty and hospital surgery	Clinical signs of various injuries of soft tissues, chest and abdominal cavity	Diagnose and provide first aid to injured people

4. The content of the topic of the lesson.

Dressings are distinguished: soft and hard fixed (fixing) dressings Fixed dressings - immobilizing and corrective - dressings with traction, are mainly used to treat patients with injuries and diseases of the musculoskeletal system. These include plaster casts, tires and apparatuses. Soft dressings consist of a dressing that is applied directly to the wound to fix it.

There are simple soft (protective and medical), pressure (hemostatic) dressing and occlusive dressing, which is applied to injuries of the chest. Dressing is usually done in the dressing room. By dressing is understood a medical diagnostic procedure, which consists of removing an old dressing, performing preventive, diagnostic and therapeutic measures in a wound and applying a new dressing. To fix the dressing use a gauze, knitted tubular bandage, mesh-tubular medical bandage "Retelast", headscarves made of Bavaria tissue, glue, collodion, adhesive plaster

The imposition of hard and soft dressings :

A) Overlay adhesive, klaavo-plastira, Leonovich dressings.

The adhesive bandage.

For patches - stickers applied collodion, kleol, glue BF - 6, Plastova, lfusa, etc. Collodion is a solution koloksilina in ether and in alcohol. Evaporation of the solvents of the collodion shrinks in a solid film that tightly adheres to the skin. Widely collodion bandages are used to close surgical wounds when used collodion stickers that save the dressing and do not limit movements of the patient. The wound impose several layers of sterile gauze, over which put the flattened gauze that goes over the edge. The free edge of gauze moistened with collodion. The disadvantages of collodion dressings are unpleasant sensations in a result of collection of the skin on the place of smearing with collodion, especially when re-application, because after each removal of the sticker places that are smeared with collodion, should be cleaned with alcohol or ether, and then dry wipe cloth.

Cleal - consists of 45 parts of powdered rosin, 1 part of vegetable oil, 37 parts of ethyl 95% alcohol and 17 parts of ether. It does not contract and does not irritate the skin. The skin around the imposed bandage smeared with a cotton swab moistened with cleol and waiting for 1-2 minutes, until cleol a bit dry, after which the entire oiled area, cover tight with gauze, which is firmly pressed against the coated kleola the surface of the skin. The free edge of the napkins sticking to the leather, cut with scissors or folded on top of the bandage if necessary to Supplement kleol sticker bandaging

Clay-BF-6 - proposed by Shkolnikov, used to lubricate minor injuries, mainly fingers, better after previous treatment of the wound with tincture of iodine to prevent the development of wound infection. After the glue dries, an elastic film is formed, which does not need additional dressing, which is especially important in industrial enterprises where minor industrial injuries occur. To cover the suture line after operations and protect the skin, a film-forming solution of acrylate-Plastubol, which is applied by spraying, is used. After drying, a protective film forms.

Lifusol- is an aerosol film-forming drug. Apply by spraying from a balloon for 2-3 seconds. After 30 seconds, a strong transparent elastic film forms on the skin. Spraying is repeated 2-3 times with pauses of 15-30 seconds to dry each ball. The film remains on the skin for 6-8 days and can be removed with acetone, ether, chloroform or alcohol. The advantage of Lifusol is ease of application, application speed, the ability to monitor the condition of the wound without changing the dressing, waterproof film, which allows patients to wash

Leykoplastyr bandage-Dressings on the wound held together with sticky plaster, and these strips go on bare skin on both sides of the bandages and firmly stick to her, holding the dressing on the wound. Usually applied several strips of adhesive tape parallel to each other at one or another distance depending on the size of the bandage. Small leykoplastyr bandage can be made from a cross like the cod patch. Lamblasting bandage can also be applied to convergence the edges of the granulating wounds, for the treatment of bone fractures by the method of constant traction, especially in children.

B) Bandage application

Bandage of the bandage is the most common because they are simple and reliable, because the bandages are an essential attribute of medical institutions of any level.

A bandage may rolled up (single-headed bandage), while brush rolled is called the head, and that is not rolled - the beginning of the bandage. Bandage, rolled up from both ends until the middle is called the double-headed bandage. The back side of the bandage which faces part of the body called back, but the opposite - CARICOM, and when strapping Cherevko should be turned outward to the bandage easily and freely could roll out on a surface bantamoi parts of the body. The bandage when the bandage held in the right hand at an angle and return toward the one who bandage (Fig.2). The bandage is wound under a slight depression, but the bandage should not be very tight, so as not to cause compression of tissue and circulatory disorders in the limbs bandaged. The basis of any bandage is round or round, which occurs when wrapped around any part of the body. The first coil is superimposed obliquely, in order to hold the end of the bandage, and the next turn he was covered.

Dressing Rules:

1. During the dressing, you need to face the patient as much as possible.
2. From the very beginning of the dressing, it is necessary to ensure that the part of the body being bound is in the correct position.
3. The direction of the turns should be the same in all layers of the dressing.
4. The width of the bandage should be selected so that it is equal to or greater than the diameter of the bandaged body part.
5. The bandage must be held in hand so that the free end forms a right angle with

the hand in which the bandage roll is located.

6. Bandaging need to start with the application of a simple ring so that one end of the bandage protrudes from under the next turn, which is superimposed in the same direction. Having bent and covering the tip of the bandage with the next turn, it can be fixed, which greatly facilitates further manipulations.

7. Bandaging should start from the narrowest point, gradually moving to a wider one.

8. The dressing is completed in a circular coil and secured in this way:

1) the end of the bandage is cut with scissors in the longitudinal direction, both ends cross and tie, and neither the cross nor the knot should lie on the wound surface.

2) the end of the bandage is pinned to previous rounds with a safety pin.

3) the end of the bandage is bent over the last circular motion

A piece of bandage about 1 m long is symmetrically superimposed on the crown with ends hanging freely on the sides of the head. At the level of the superciliary arches and the occipital protuberance with another bandage Fig. 1.

Bandage "Cap "

The bandage "cap" is applied: the first circular coil under the free ends of the cut.

With each subsequent turn, a loop is made around the free end, then the bandage is sent to the back of the head, goes to the other side of the head, where again the loop is made around the free end, and the bandage goes to the free end along the frontoparietal part of the head.

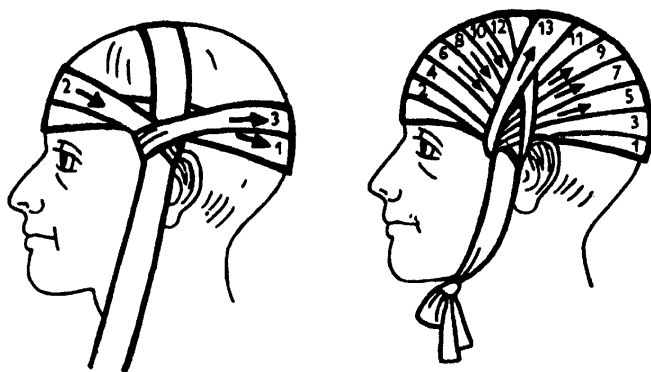


Fig. 1. Cap "cap"

Moving the bandage at each subsequent turn, form a bandage that completely covers the surface of the head. In conclusion, the free ends are tied under the chin

Dressings for one and both eyes.

One eye patch. (Fig.2) When applying a bandage to the right eye, the bandage is usually held it the right hand and applied from left to right. With a blindfold on the left eye, it is more convenient to transfer the bandage to the left hand and do the blindfold from right to left.

The first is a fixative circular coil around the head. The following turns pass over the ear on the healthy side and under the ear on the affected side, gradually closing the damaged eye. The dressing ends with a circular fixing loop.

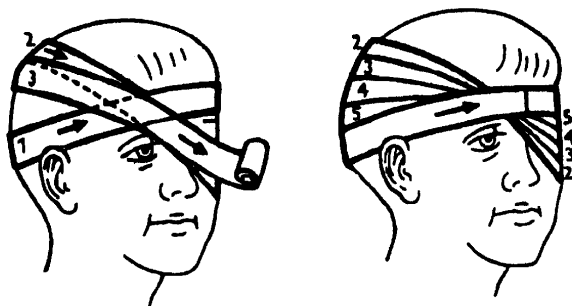


Fig. 2. A bandage on one eye.

A bandage on both eyes. (Fig. 3) After the first circular turn around the head, the

bandage is passed through the crown and obliquely descends through the forehead, closes the left ear, bends around the head under the occipital protuberance and the right ear, and goes obliquely upward, closing the right eye. The turns cross in the nose. The following turns gradually cover both eyes. The dressing ends with a circular loop at eye level. Auricles remain open.

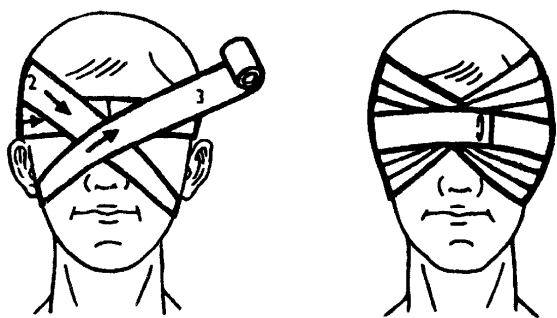


Fig. 3. bandage on both eyes.

Bandage "Bridle"

It is used to cover the lateral surfaces of the face, temporal region, forehead or crown, as well as to fix the lower jaw and cover the chin. (Fig. 4) The first circular, fixing coil is superimposed in the direction from the healthy to the damaged side. Further, the bandage is carried to the ear on the damaged side, obliquely descends behind it, held under the occipital protuberance, under the ear on the healthy side, through the chin is displayed on the damaged side, sent up to the crown. Then the bandage is held down, covering the auricle on the healthy side, passes under the chin, closes the other ear and returns to the crown. With the next turn, the bandage goes down to the healthy side, passes along the posterior edge of the auricle to the back of the head, leads to the damaged side, is held along the lower edge of the lower jaw, passes under the ear on the healthy side to the back of the head. Then the bandage is again held under the chin and before the ear on the healthy side returns to the crown, then above the ear on the damaged side it returns to the back of the head, from it to the chin and back through the damaged side to the crown. Although the dressing is one-sided, it is almost symmetrical. The difficulties associated with its imposition are offset by its high reliability.

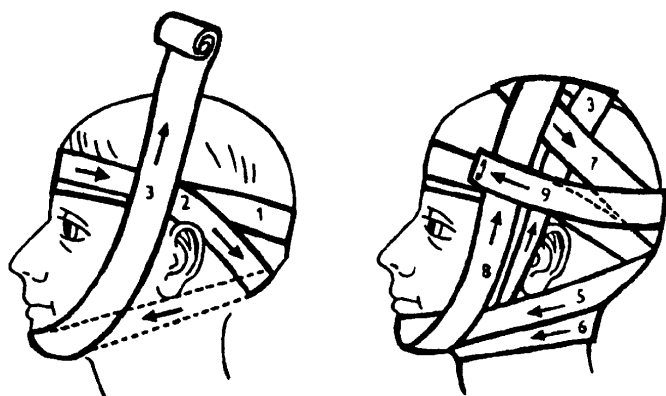


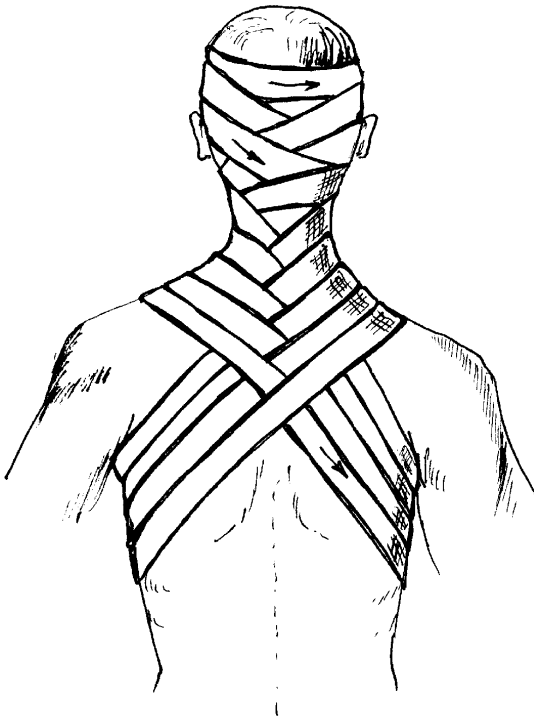
Fig. 4. Bridle Bandage

The double-sided dressing "Bridle" is simpler than described above, and completely closes the chair, including the chin. The front surface of the face, as well as both auricles, remains free of bandage. The same turns of the bandage begin over one ear, then the

bandage passes along the crown of the head and descends in front of the other ear, passes under the chin and rises up to the crown of the head. Then the bandage is held to the other side, returns to the nape above the ear, from there to the chin, then the bandage rises obliquely along the upper jaw to the crown, moves to the back of the head and again under the ear passes under the chin and rises up to the crown. In similar turns, the entire bandage is formed. So that it does not slip, it is recommended to use a narrow bandage (4-5 cm.) And rewrite the turns.

Cross dressing on the back of the head with the transition to the back (Fig. 5)

It well closes the back of the head and the back of the neck, and the passages of the bandage cross over the area of damage. The bandage begins with 1-2 circular movements of the bandage 6-8 cm wide around the head. Then the bandage is led above the left auricle and lowered sequentially on the back, right, front and left side of the neck to the forehead, crossing the previous move and so on. The disadvantage of the bandage is the possibility of squeezing the neck, as the bandage moves lie across its front surface. Before bandaging, be sure to apply a layer of cotton on the front of the neck. When bandaging the lower part of the neck, it is advisable to supplement the bandage round tours with strokes of the type of a cruciform bandage on the back section that goes through the axillary sections. Thus, the area of damage is covered completely and the dressing does not move during the movements of the chairman and body.



Spike bandage on the shoulder joint (Fig. 6)

Used to cover the shoulder joint and armpit. The ascending cross bandage begins with the first fixing coil on the shoulder near the axillary site. Further, the bandage is carried out under the arm to the outside of the shoulder joint, goes around it and goes to the back, is passed through the armpit from the other side to the front surface of the chest,

then along the front surface of the chest to the front surface of the bandaged shoulder, under it under the arm. Then an 8-shaped coil is formed with a cross on the front surface of the shoulder.

The descending cross bandage begins with the first fixing loop around the chest at the level of the axillary areas, then the bandage is carried out from the axillary cavity of the healthy shoulder obliquely along the front surface of the chest to the front surface of the tied shoulder joint, goes around it, passes under the arm forward and up to the back and stretches through the armpit of the opposite shoulder. In this way, 8 descending turns are formed with a cross on the front surface of the bandaged shoulder joint. The dressing ends with a fixing loop in the upper third of the shoulder

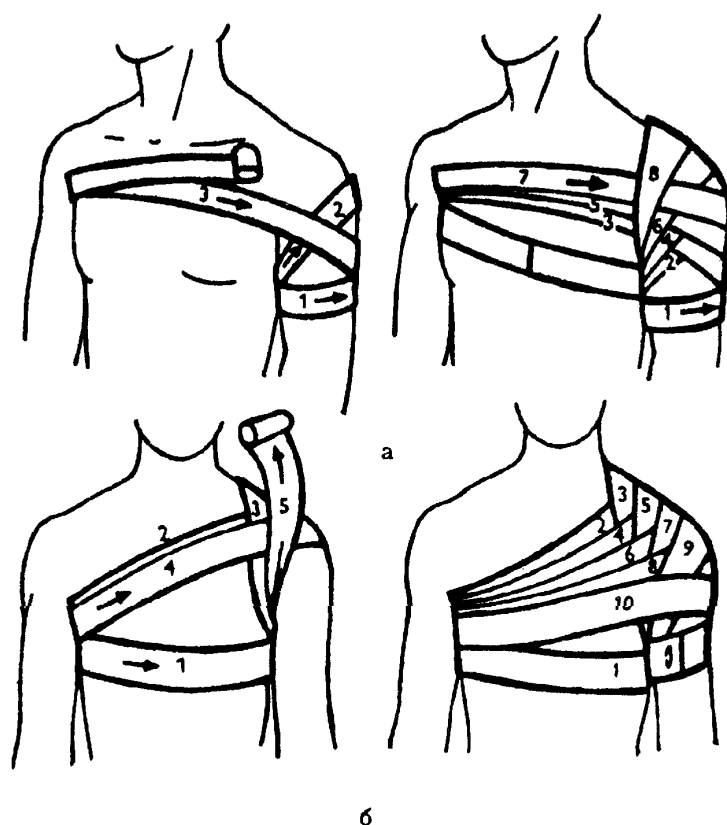
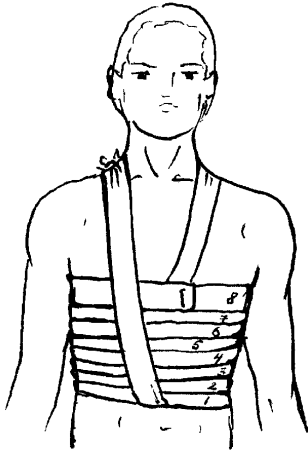


Fig. 6. Cross bandage on the shoulder joint.

Spiral bandage on the chest (Fig. 7)

The bandage 1.5 m long is applied across the shoulder girdle. On top of the hanging bandage, a spiral bandage is applied with a wide bandage to the axillary hollows with a wide bandage. The hanging ends of the bandage tie are pulled, shifted to the midline and, having thrown over another shoulder girdle, are tied together in front of the bandage. The bandage-tie tightly fixes the spiral bandage, makes it motionless. It is possible to use two bandages-ties.

Fig. 7 Spiral bandage on the chest.
Fig. 7 Spiral bandage on the chest.

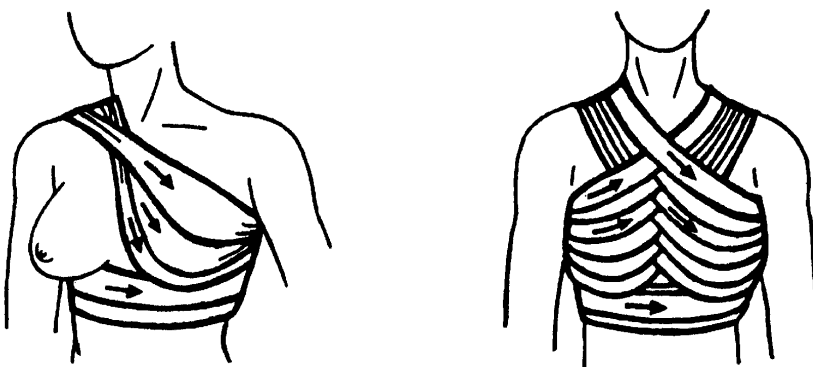


Breast dressings (Fig. 8)

A bandage that supports one mammary gland. The first round is carried out around the chest under both mammary glands in the direction from healthy to damaged, then the bandage is passed through the back to the shoulder of the healthy side, goes around it and goes down obliquely, covering the damaged mammary gland, starting from its lower sections. The following turns cover it completely.

A bandage that supports both mammary glands. The first turns of this bandage are similar to those described above, but after the turn that covers the mammary gland, the bandage is not applied to the opposite shoulder girdle, but passes across the back, bends around the body, covers the second mammary gland and rises to the opposite shoulder girdle in front. Gradually, such turns cover both mammary glands. If the dressing should also be oppressive, then eight-shaped turns are alternated with circular ones, covering both mammary glands.

Fig 8. Bandages on one and two mammary glands.

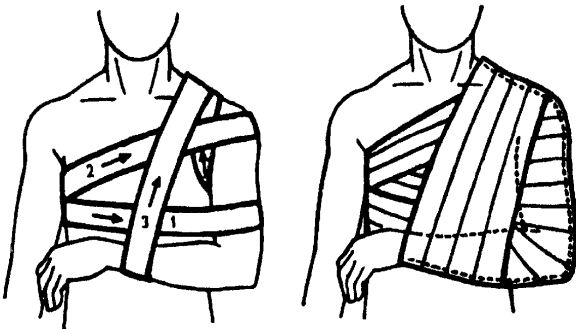


Deso Dressing (Fig. 9)

There is a very complex dressing and is used if necessary to immobilize the upper limb by pressing it to the chest. Before applying the dressing, it is recommended to

inspect the armpit area, powder it with talcum powder and put a cotton pad to prevent maceration and to absorb sweat. The pillow is fixed with a bandage or simply laid without special fixation. The nature of the initial turns is determined by the fact that the bandage should both fix and support the limb. The first circular turn is carried out from the back through the axillary cavity of a healthy arm along the chest, bypassing the damaged arm and pressing it to the chest, then the bandage passes along the back, through the axillary region, it is led obliquely along the front surface of the chest to the shoulder of the injured arm. Such complex coils gradually form a bandage. A healthy hand remains free. To give rigidity to such a dressing, you can use starch bandages at the last stages of its formation, which should not be directly in contact with the surface of the body.

Fig. 9 Bandage Deso.



Turtle (tiled) bandage on the elbow and knee joints (Fig. 10)

The bandage is applied at the physiological position of the elbow joint, both converging and diverging. In the first case, it begins with a fixing loop under the elbow, then the bandage is obliquely held along the ulnar fossa on the shoulder, which wraps behind. Then 8-shaped turns that converge at the process of the ulna and cover the entire joint, in the middle of which the last fixing coil is superimposed.

With a bandage that diverges, the first fixing coil is applied over the process of the ulnar bone and then 8-shaped turns diverge from the middle, gradually closing the elbow joint. The bandage is crossed on the front surface of the bandage limb.

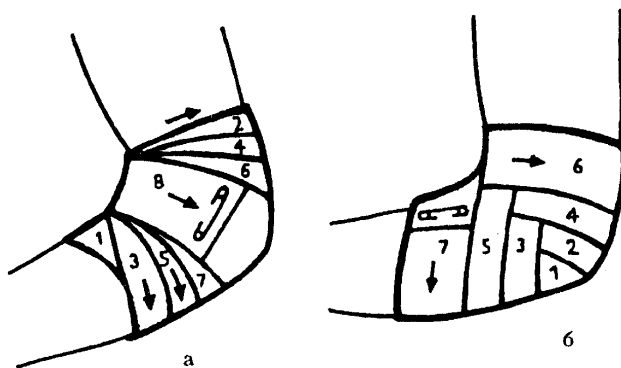
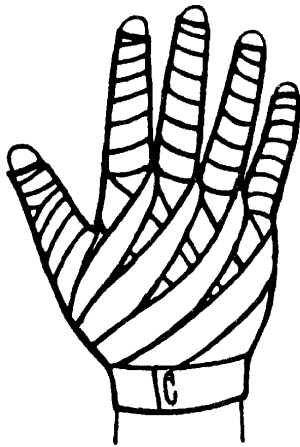


Fig. 10. Tile bandage on the elbow joint. A- converge; B- diverge.

Bandage "knight's glove" (Fig. 11)

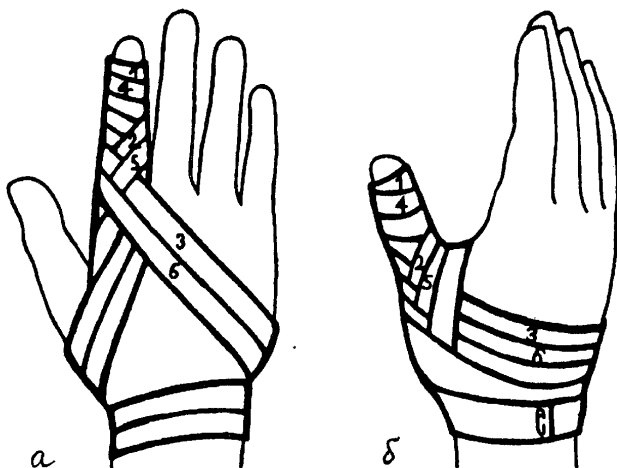
The need for such dressings arises when it is necessary to bandage the brush, leaving the fingers free, when sequential bandaging of all fingers is necessary (for skin diseases, for burns). The bandage begins with the first fixing loop on the wrist, then the bandage is held on the back of the hand, is carried out through the base of the fingers and returns to the wrist. On the left hand, such a bandage begins with the 5th finger, and on the right hand with the first narrow bandage (2-3 cm) in the state of pronation of the hand (palm down). The bandage is rolled across the rear of the brush to the fifth finger, with the spiral movements covering the fifth finger, starting from its tip. Next, the bandage is sent along the rear of the brush on the wrist, the previous one is crossed, and, having made a circular turn, from the palm side of the wrist is transferred along the back surface to the fourth finger. The dressing is completed with circular strokes around the wrist. To fix the bandage, it is necessary to carry out circular movements around the wrist when transferring the bandage from finger to finger.



Dressings on a finger (spiral, spiky)

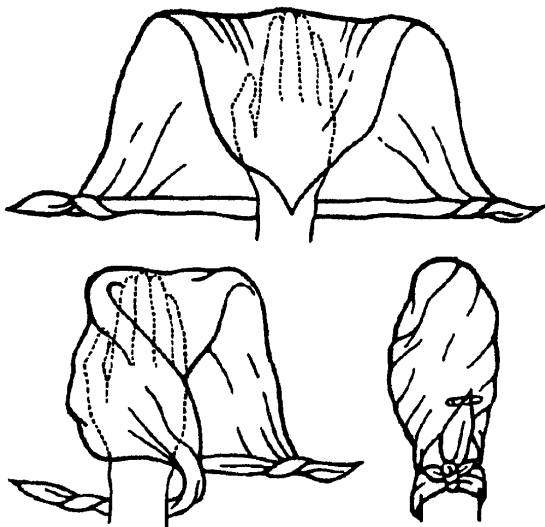
The bandage on the finger (Fig. 12) begins with a circular loop at the base of the finger, then the bandage is held on the back of the hand to the wrist, around which the fixing loop is made, and returns back to the base of the finger. As the finger is bandaged from the tip (the last phalanx) downward, the spiral dressing technique is used, and when approaching the base of the finger and moving to the back of the hand, it is replaced by a spike, forming an incomplete "glove".

Fig. 12. a - spike-like bandage on a finger.
b- bandage on a thumb



Upper limb bandage

Kerchief dressing on the brush (Fig. 13) - the scarf is spread on the table, its base is tucked once or twice so that a firm girdle is formed 1-2 cm wide. Then the bandaged hand is placed with the palm up or down, depending on the location of the damage so that the fingers are pointing to the top of the scarf. And then the upper corner of the scarf is discarded, covering the brush. With the correct position of the hand, he should be in the wrist joint. After that, the ends of the scarf are wrapped and crossed above the wrist joint, closing the arm on both sides, wrapped around the arm and tied in a knot. To fix the bandage, you can slightly extend the top of the scarf from under the knot and tie it to one of the free ends. With this bandage, you can leave your thumb free, thereby expanding the

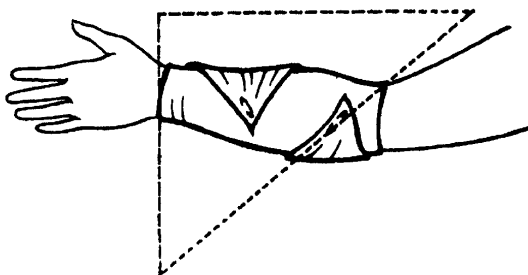


functionality of the hand.

Handkerchief on the forearm (Fig. 14)

The scarf is superimposed on the forearm and is tightly wound around it. The free ends are fixed with studs or adhesive tape.

Fig. 14. Handkerchief on the forearm.

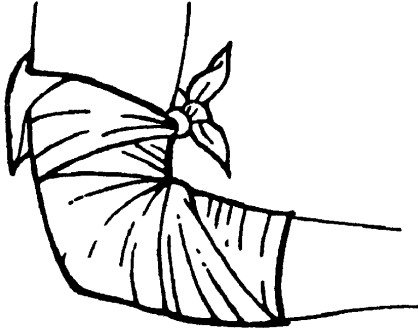


Elbow bandage (Fig. 15)

The hand is located on a scarf spread out on a table so that the forearm is on the basis of the scarf, and the apex is on the back of the shoulder. The free ends of the scarf are wrapped on the palmar surface of the forearm and intersect at the level of the elbow.

Then they rotate around the shoulder, pressing down the top of the scarf, and tie a knot over the elbow bend. Nodes in the elbow bend can cause swelling.

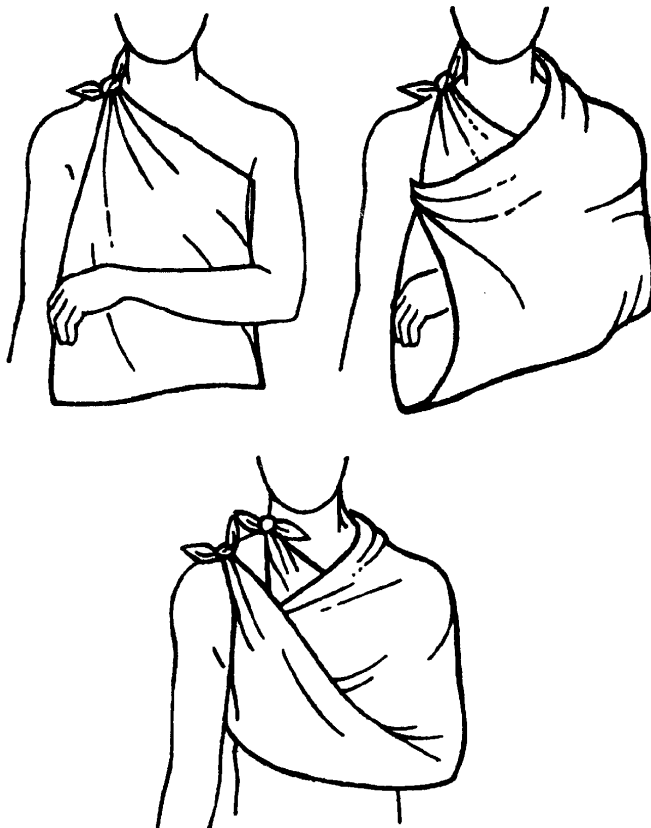Fig. 15. Headband on the elbow.



Shawl bandage on a shoulder (fig. 16)

Formed from one or two scarves. When using one scarf, it is superimposed on the outer surface of the shoulder so that the top of the scarf is directed to the neck. Both ends of the axillary site, where they intersect and are displayed up. Over the shoulder joint, the ends are tied with a knot, and to strengthen the bandage, one of them can also be tied with the top of the scarf. But such a bandage, even if it is correctly and tightly connected, can slip, so it is often fastened with a loop of lace or bandage overturned around the neck and tied to the top of the scarf.

When using two headscarves, one of them serves as a bandage, as described above,



the other is turned into a tape and used to secure it. And this can be done in two ways.

The middle of this scarf is located under the arm of the other hand, and the ends are thrown over the body and connected with the free top of the first scarf, or vice versa, the middle of the second scarf covers the bandage on the shoulder, the free ends are tied under the arm, and the top of the first is fastened to the second with a pin.

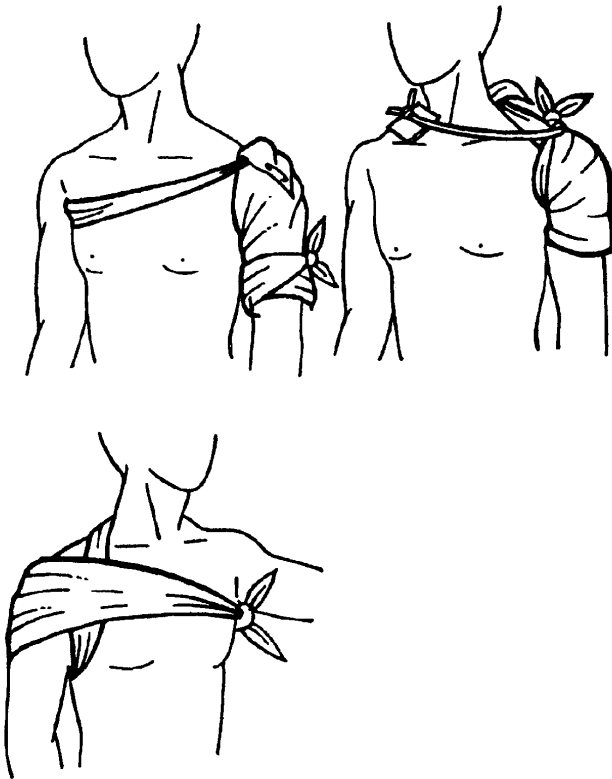


Fig.16. Shoulder bandage

Supporting dressing with a square scarf (Fig. 17).

A square scarf is placed in front of the chest under the injured arm. The upper corners are tied in a knot over the opposite shoulder, closer to the neck. The posterior lower end bends around the shoulder of the damaged arm and extends from front to back under the opposite armpit. The front end wraps around the forearm and rises up onto the shoulder of a healthy arm, where both ends are tied in a knot.

5. Indicative card for independent work with literature on the topic ” Desmurgy ”

Main tasks	Directions	Answers
To learn		
Classification	Establish a classification of bandages and dressing types.	
Types, clinical signs of	Name the types of traumatic	

closed and open injuries	injuries, characterize the main clinical manifestations of different types of injuries	
Volumes of first aid for victims with various traumatic injuries and ways of their transportation.	Name the volumes of first aid for victims with injuries	

6.1. Materials for self-control.

A. Questions for self-control.

1. Name the types of dressing depending on the purpose.
2. What is the functional position of the limb?
3. Name the classification of dressings.
4. How to apply various soft dressings?
5. The technique of applying bandages to the head.
6. Why is cleol made? What is it used for?
7. What types of bandage tours do you know?
8. What is the difference between spiral and circular dressings

B. Tasks:

Overlay: bandage ties Deso, Velpo.
 occlusive dressing
 headband ("cap", Hippocrates cap)
 bandage for injured hands.

C. Tests for self-monitoring:

1. The patient has a postoperative wound of the epigastric region. What dressing should be used to prevent infection of the wound?
 1. bandage;
 2. gauze;
 3. glue;
 4. one-piece;
 5. circular.

2. The patient has extensive biting wounds of the right forearm. What is the most comfortable dressing?
 1. glue;
 2. plaster;
 3. spiral with an inflection bandage;
 4. circular;
 5. circular gypsum.

3. The patient has a wound of the upper third of the left thigh, in the region of the greater trochanter. What bandage should he apply?

1. T-shaped;
2. eight-shaped;
3. sling;
4. spike-like;
5. turtles.

4. The boy fell face down on the ground and nose bleeding immediately appeared.

What dressing should be applied to provide first aid to the victim?

1. none;
2. crushing;
3. sling;
4. special;
5. patch;

5. The victim has five wounds in the scalp. What bandage should he put on?

1. bandana;
2. plaster;
3. glue;
4. bridle;
5. cap.

6. The victim has a fracture of the lower jaw. What bandage needs to be applied in emergency care?

1. cap;
2. scaphoid;
3. The cap of Hippocrates;
4. bridle;
5. the scarf.

7. The patient revealed purulent mastitis of the right breast. Which dressing is best used?

1. Deso;
2. spiral to the chest;
3. circular to the chest;
4. supporting the mammary gland;
5. pressing on the mammary gland.

8. A patient with a dislocation of the shoulder must be given first aid. What bandage does he need to apply?

1. bandage;
2. bandana;
3. gypsum;
4. spike-like on the shoulder;
5. special.

9. The most serious mistake when applying a bandage to the neck area are:

1. quite free;
2. not fixed;
3. longing;
4. used a wide bandage;
5. superimposed with a very large number of tours.

10. Dressings on the chest are fixed with a bandage:

1. spiky;
2. turtle;
3. Velpo;
4. circular;
5. spiral.

11. Dressings should meet all requirements except:

1. hygroscopicity;
2. elasticity;
3. sterilization capabilities without loss of quality;
4. irritating effect on tissue;
5. capillarity.

6.2. Tests and tasks for verification of initial level of knowledge

1. Woman with 10-year-old boy appealed to You due to the fact that the child suffers from pain in the right elbow joint. Boy 6 hours ago in the outpatient clinic, for infected abrasion of the elbow joint, after treatment was wrapped up in bandages. When the inspection is determined by a light cyanosis of the right forearm and wrist, the bulging of the subcutaneous veins, even when lifting arms up.

What happened? How to help your child?

2. The reception was attended by 40 year old man, who is worried about itching of the left forearm. Three days ago, got thermal burns of I-II degree. On his forearm was imposed aseptic bandage. During the inspection it is established that the bandage on the dorsum of the middle third of the forearm soaked in a yellowish-gray discharge. How to remove the bandage?

3. In the emergency Department delivered a man of 34 years with incised wound of the Palmar surface of the middle third of the right forearm. According to the victim, the wound 1.5 hours ago on the street struck with a knife by unknown. Carried out the toilet of the wound imposed by primary seams. Nurse bandaging material on the wound, secured with a bandage, tying the ends of the bandage in a knot over the wound. After that, she introduced him (the patient) subcutaneously 0.5 ml tetanus toxoid and 3000 ME tetanus toxoid. What mistake is made in the technique of bandaging?

4. Patient K., 20 years in connection with a trauma of cervical spine and spinal cord injuries, with the aim of it held emergency decompression laminectomy. The wound on the back of the neck is sewn closed gauze. What roller bandage You apply for fixation of dressings?

5. You ambulance doctor. You've been called to a patient with a penetrating wound of the chest on the right. The victim's condition is severe. He instinctively covers a wound with a hand, leaning on her right side. On examination, the wound marks the suction of air through it during inspiration, and when you exhale the air with the noise coming out of it. Your actions?

6. Patient S., 28 years old, an autopsy of septic bursitis of the elbow. Bag of promita with an antiseptic solution, drained with a pellet soaked in hypertonic sodium chloride solution, covered with gauze. As You secure dressings?

7. Patient S., 36 years old, suffered during a road accident. A cut profusely bleeding wound in the right temporal region and extensive round-log laceration on the outer surface of the right shoulder joint. Signs of a shoulder fracture no. What bandage should be placed to the patient when providing first aid?

8. You're a casual witness of the accident: the child burning boiling water the right hand, screaming in pain. On the dorsum of the fingers and hand appeared bubbles. The home kit is the solution furacillinum (1: 5000) and packaged in a sterile bandage. With the aim of first aid which bandage to apply to the victim?

9. In a rural district hospital delivered a 52-year-old working farm with a chopped wound of the right parietal region, which covers the victim himself with a handkerchief. What volume of medical care must be provided to the patient?

10. As a pediatrician You examined the child's home, recommended to impose on her right ear hot compress. The child's mother, referring to the inability to perform this procedure, asked You to help. How to put a hot compress on the ear and with the help of a bandage to fix it?

11. Physician rural outpatient clinic asked the boy of 11 years, which about an hour ago while playing hockey I got hit with a stick in the area of the left eye. Was immediately given first aid in the form of an eye snow. Visually determined moderate hyperemia of the eyeball, corneal erosion. On palpation, the eye painful. The diagnosis: blunt trauma to the left eye. What volume of first aid should be provided to the child and to secure dressings?

12. Male 47 years old, fell off the bike. Complains of pain in the right shoulder girdle. Visually marked swelling, deformity, tenderness and crepitus in the projection of the middle third of the right clavicle. The pulse on the right radial artery satisfactory. What

roller immobilizing bandage, apply?

13. After reduction of traumatic dislocation of the right shoulder of the victim is necessary to fix the right upper limb on average 1 to 1.5 weeks. What roller immobilization bandage You apply?

7. References:

General:

1. General Surgery. Textbook for students of higher medical educational establishments / [Lihonenko O.V., Chorna I.O. , Zubaha A.B., Khimich S.D et all.]; Edited by Prof. S.D. Khimich, Prof. M.D. Zheliba Kyiv AUS Medicine Publishing, 2019.- 608 p.
2. General Surgery. Textbook for students of higher medical educational establishments / [Lihonenko O.V., Chorna I.O. Khimich S.D et all.]; Edited by Prof. Ja.S.Bereznickij, M.P.Zacharash, M.P.Mishalov,. Vinnica: New book, 2019-344c
3. Methodological recommendations for classroom and independent work of students.
4. General Surgery / Ed. S.P.Zhuchenko, M.D.Zheliby, S.D.Himicha - Kiev.: Health, 1999.
5. Cherenko MP, JM Vavryk General surgery in anesthesiology, intensive care, and the basics of patient care - Kiev.: Health, 1999.
6. Gostishchev VK General Surgery: Textbook. - Moscow: Medicine, 1993
7. Gostishchev VK "Guide to practical training in general surgery." M., "Medicine" - 1987.

Additional:

1. AA Simodeyko, SS Philip A. Boldizhar General Surgery Questions and Answers. Uzhgorod, "Willow" - 2005.
 2. SM Genyk, MV Prokopishin, VM Rat and others. Case Studies on hirurgii.Ivano-Frankivsk, "Lileya-NV" - 2003.
 3. AA Simodeyko, SS Philip A. Boldizhar, V. Pant Practical skills in general surgery patient care. Uzhgorod, Uzhgorod National University. - 2001.
- Website akady <http://www.umsa.edu.ua>
 - Website department of general surgery http://www.umsa.edu.ua/kaf_zaghir
 - Library UMSA <http://www.umsa.edu.ua/pidrozdilhome/biblioteka/biblhome.html>

The distribution points are awarded to students:

At mastering topic number 1 to module 1 for training activities for students rated a 4-point scale (traditional) scale, which is then converted into points as follows:

rating	Points
5 (excellent)	5
4 (good)	4
3 (satisfactory)	3
2 (poor)	0

Guidelines prepared
 assistant, Department of General Surgery
 Yaroshenko R.An._____